

# MEG Studies of Stroke Outcomes

Bowyer SM<sup>1,2,3</sup>, Weiland BJ<sup>1</sup>, Straub M<sup>1</sup>, Shukla N<sup>2</sup>, Mason KM<sup>1</sup>, Moran JE<sup>1</sup>,  
Tepley N<sup>1</sup>, Mitsias P<sup>1,3</sup>, Barkley GL<sup>1,3</sup> and Silver B<sup>1,3</sup>

<sup>1</sup> Henry Ford Medical Group, Detroit, Michigan USA

<sup>2</sup> Oakland University, Rochester, Michigan USA

<sup>3</sup> Wayne State University, Detroit, Michigan USA

[sbowyer1@hfhs.org](mailto:sbowyer1@hfhs.org)

## ABSTRACT

This study utilized MEG to detect neurologic damage and recovery after stroke. We recruited 11 patients who had recent strokes. Spontaneous cortical brain activity was recorded with MEG for 18 minutes. Data were sampled at 254Hz, DC-100Hz, filtered from 1-7Hz 7-15Hz, 15-25Hz and 25-50Hz and imaged with MR-FOCUSS. Coherence analysis was then performed and compared to the location of the stroke lesion. In stroke patients, coherence in the delta frequencies, (1-7Hz) known to represent the breakdown of networks between neurons, was seen 2 days after stroke in the lesion penumbra, and continued for 5 weeks. These delta frequencies lessened over time on subsequent scans. On the initial MEG scan, 15-25Hz activity was seen surrounding each patient's lesion. After 4 weeks, regions in the contralateral hemisphere showed coherence in the mirror area of the lesion, suggesting that the contralateral hemisphere began assuming limited function previously demonstrated by the lesion area. This activity lasted for approximately 3 months. In control subjects scattered brain regions of coherence were imaged but none of these areas were consistently imaged over time. This study confirmed that MEG can determine the status of recovering coherence in neuronal networks after stroke.

**KEYWORDS:** MEG, Stroke, Coherence Imaging,

## INTRODUCTION

New or recurrent stroke affects 700,000 people per year in the United States [1]. Over 4 million Americans now live with the aftereffects of stroke [1]. Most drug therapies for stroke focus on acute treatment (i.e. thrombolysis) or secondary stroke prevention. Recent experimental studies on functional recovery after stroke have concentrated on the use of pharmacological treatments such as sildenafil citrate (Viagra) [2], erythropoietin (EPO) [3], and statins [4] which have shown promise in neuronal and vascular remodeling. Some of these treatments are now in phase I/II studies. Presently no precise imaging tool provides evidence of treatment induced neurogenesis in stroke patients or signals changes correlated with outcome. The neurological outcome for a stroke patient is measured by his/her score on the National Institutes of Health Stroke Scale (NIHSS). This is a standardized, validated

instrument that assesses severity of neurological impairment after stroke. This is not an imaging technique or histological assessment, but a clinical grading of the ability to perform functional tasks such as, movements of legs and arms, eye gaze, level of consciousness, ability to talk, and attention to spatial orientation. Functional imaging measurements of stroke recovery would be clinically useful as a tool for gauging stroke recovery and effectiveness of medical treatments. The current challenge is determining methods to identify recovery-related therapeutic targets and imaging prognostic factors [5].

In this study we used MEG coherence imaging for estimating cortical connectivity to evaluate the integrity of a stroke patient's cortical network. Recently, techniques have been investigated that calculate coherence between sources of MEG imaged brain activity. These techniques vary in analysis methods applied to MEG data, the number of sources for which paired coherence can be calculated, and the use of phase synchrony in place of coherence. MR-FOCUSS is capable of imaging both focal and extended cortical activation [6]. We have combined MR-FOCUSS with Independent Component Analysis (ICA) that enhances the imaging of brain electric activity [7]. We investigated the utility of MEG for detecting neuronal changes indicative of brain repair in the cortex after stroke. The extent and severity of neuronal damage may correlate with recovery or failure thereof. MEG has the potential for defining functional outcome after stroke and enhancing existing prognostic indicators (NIHSS & MRI).

## METHODS

We studied patients with recent ischemic stroke. All patients were studied with the NIHSS which was performed at the time of MEG imaging by a neurologist certified in performance of the NIHSS (B. Silver). The NIHSS scale is a quantified neurological examination with 11 elements assessing consciousness, eye movement, vision, facial strength, limb strength, coordination, sensation, language, speech clarity, and spatial attention. Scores range from 0 – 38 with 0 being normal

and higher scores indicating decreased neurological function. The exam takes approximately 5-10 minutes to complete.

A 148-channel MEG system (4D Neuroimaging) recorded spontaneous cortical brain activity for 18 minutes. Data were sampled at 254Hz, DC-100Hz. Data were separated into 4 frequency bands of 1-7Hz (Delta/Theta), 7-15Hz (Alpha), 15-25Hz (Beta), and 25-50Hz (Gamma). Results were analyzed with MR-FOCUSS, a current distribution analysis technique capable of imaging simultaneous activity in multiple cortical structures and coregistered to each volumetric MRI. Coherence analysis of the MEG imaged results were compared to lesion location on the MRI.

## RESULTS

11 patients with diagnoses of recent ischemic strokes were studied. Four patients did not return after the first study for further MEG scanning. Of the remaining patients, five had two scans, one had three scans, and one had four scans. The study population included 8 men and 3 women, mean age of 51 years (range 29-69), all right-handed. Ten patients presented with ischemic and one presented with hemorrhagic stroke. The stroke location was brainstem in one, subcortical hemispheric in 4, and cortical in 6 patients. The median NIHSS at the time of the initial scan was 4 (range 1-22). MEG scanning was first performed at a median of 4 days post-stroke onset and then, where possible, at about 60, 120 and 180 days. These patients were compared with five controls who had two MEG scans separated by 4 weeks.

Coherent brain activity in the Delta range (1-7Hz), surrounding the lesion, was seen three days after stroke and continued with no significant change through the second scan (Fig 1). Across all time points the average correlation coefficient for run to run coherence was  $r=0.77\pm0.09$ , 95% confidence limits. Between day 57 and day 120 as the delta band resolved, the coherence was significantly reduced,  $r=0.565\pm0.02$ , as compared with the run to run correlation. These lower frequencies correlate with breakdowns in the neuronal networks [8]. On initial MEG scans, Beta (15-25Hz) activity was seen around the lesion (Fig 2). Higher frequency activity is correlated with axonal sprouting and restoration [9-11]. After 4 weeks, the contralateral hemisphere showed Beta coherence in a mirror area to the lesion; activity lasted for nearly three months. Changes in the Beta coherence was significant between the 57, 120 and 179 day time points ( $r=0.69\pm0.02$  and  $r=0.65\pm0.02$ ). Coherent Alpha band brain activity (7-15 Hz) was continuously active over the entire interval (Fig 3). At 8 weeks Gamma band (25-50Hz) activity mirrors the area of the lesion (Fig. 4).

### A. Delta/Theta (1-7Hz)

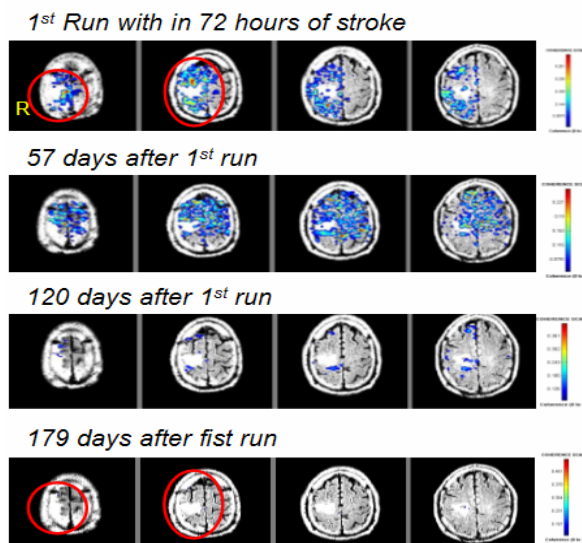


Fig 1. MRI shows localization of activated cortex around the stroke lesion in the right superior parietal area for one patient. MEG Coherence analysis from spontaneous brain activity is shown on the MRI. Circles indicate cortical areas where significant changes in Delta coherent activity occurred. This patient had a good outcome.

### B. Beta (15-25Hz)

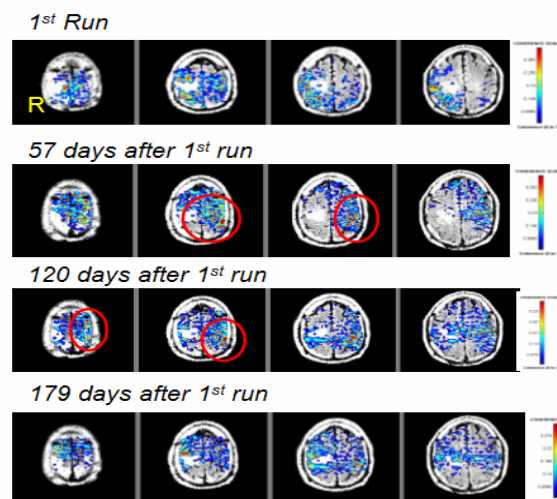


Fig 2. MEG Coherence analysis for the Beta range brain activity from same patient as shown in fig 1. Circles show Beta activity is seen in the contralateral hemisphere starting at 4 weeks after stroke and continuing for 4 months.

### C. Alpha (7- 15 Hz)

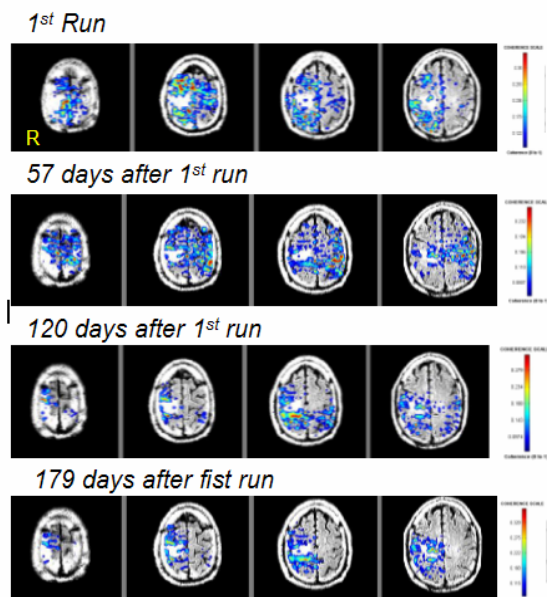


Fig 3. MEG Coherence of spontaneous alpha brain activity in same stroke patient. Alpha activity was seen in all MEG scans

### D. Gamma (25-50 Hz)

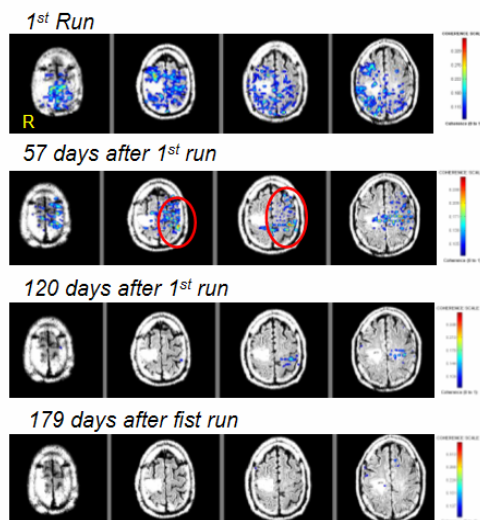


Fig 4. MEG Coherence of gamma brain activity in same stroke patient as seen in Fig1-3. Gamma frequencies are highly coherent about 4 weeks after stroke and are seen in the contralateral hemisphere.

### DISCUSSION

This study of human patients, with recent ischemic stroke, shows that slow frequencies on MEG gradually diminished with time and were replaced by higher frequencies in the contralateral region for a patient with positive outcome. We have show that MEG can non-invasively determine the status of recovering coherence in neuronal networks after a stroke. Further

studies with MEG may elucidate the basic mechanisms underlying neural network recovery following ischemic stroke.

### CONCLUSION

Imaging the magnetic fields arising from stroke patients may lead to prognostic indicators of recovery for clinical application. Changes in low frequency neuronal activation after drug therapy may help in determining drug effectiveness in restoring brain function. Further studies will investigate whether MEG can detect brain activity changes after stroke and provide clinicians with a tool for gauging stroke recovery and treatment efficacy. Low frequency signals may eventually be shown to correlate with good functional recovery. MEG may emerge as an imaging modality, useful in the early indications of good recovery or treatment. Moreover, these studies may further the basic science of the underlying mechanisms of stroke. This study may help establish MEG analysis as a biomarker for determining the prognosis for recovery after stroke, and add information to existing prognostic indicators (NIH stroke scale and MRI).

### ACKNOWLEDGEMENT

Research supported by NIH/NINDS Grant RO1-NS30914.

### REFERENCES

- [1]Stroke prevention: measuring and closing the anticoagulation gap. *The American Journal of Managed care*, 2004: p. S447-450.
- [2]Zhang, L., Zhang, RL., Wang, Y., Zhang, C., Zhang, ZG., Meng, H., Chopp, M., Functional recovery in aged and young rats after embolic stroke: treatment with a phosphodiesterase Typ5 5 inhibitor. *Stroke*, 2005. 36: p. 847-852.
- [3]Wang, L., Ahang, Z., Wang, Y., Zhang, R., Chopp, M., Treatment of stroke with erythropoietin enhances neurogenesis and angiogenesis and improves neurological function in rats. *Stroke*, 2004. 35: p. 1732-1737.
- [4]Chen, J., et al. Atorvastatin induction of VEGF and BDNF promotes brain plasticity after stroke in mice. *Journal of cerebral blood flow & Metabolism*, 2005. 25: p. 281-290.
- [5]WorkshopMeetingReport, Neuroimaging in stroke recovery: a position paper from the 1st international workshop on neuroimaging and stroke recovery. *Cerebrovasc Dis*, 2004. 18: p. 260-267.
- [6]Moran, J.E., Bowyer, S., Tepley, N, Multi-Resolution FOCUSS: A source imaging technique applied to MEG data. *Brain Topography*, 2005. 18: p. 1-17.
- [7]Moran J.E., D.C.L., Tepley N., ICA Methods for MEG Imaging. *Neurophysiology and Neuroscience*, 2004. <http://www.neurojournal.com/issue/view/33>.
- [8]Welch, K.M., Caplan L.R., Reise D.J., Siesjo B.K., Weir B., ed. *Primer on Cerebral vascular disease*. 1997, Academic press.
- [9]Zhang RL, Z.Z., Chopp M., Neurogenesis in the adult ischemic brain: generation, migration, survival, and restorative therapy. *Neuroscientist*. 2005 11: p. 408-16.
- [10]Calza L, G.L., Giuliani A, Aloe L, Levi-montalici R, Nerve growth factor control of neuronal expression of angiogenic and vasoactive factors *Pro National acad sci USA*, 2001. 98: p. 4160-5.
- [11]Chen j, Z.Z.,et. al., Statins induce angiogenesis, neurogenesis, and synaptogenesis after stroke *Ann Neurol*, 2003. 53: p. 743-51.